

Radiologic Assessment of Angular Wrist Parameters of Asymptomatic Nigerians

Omadachi S.E.¹, Gwunireama, I.U.¹, Aigbogun (Jr) E.O¹

¹Department of Human Anatomy, Faculty of Basic Medical Sciences, College of Health Sciences, University of Port Harcourt, Rivers State, Nigeria.

Date of Submission: 09-06-2017

Date of Acceptance: 16-07-2017

Date of Publishing: 12-09-2017

ABSTRACT

Background: Radiographic techniques has availed anatomists the opportunity to study human bony structure in-vivo. Normative data can assist in defining and quantifying abnormalities. This study was carried out to establish normal angular wrist dimensions of adult Nigerians. **Methods:** A total of 100 standard lateral wrist x-rays were obtained from 50 (26 males [52%] and 24 females [48%]) adult Nigerians. Three (3) angular dimensions; radial tilt, capitulate angle, and scapholunate angle were measured. Data were analysed using XLSTAT (Addinsoft Version 2015.4.01.21575). Student and paired sample t-test were used to evaluate sex, and side differences respectively. $P < 0.05$ (at 95% confidence level) was taken to be significant. **Results:** The mean values for the measured angular parameters were as follows; right and left radial tilt (R&L-RT) = $14.06 \pm 2.46^\circ$, capitulate angle (CLA) [R = $17.48 \pm 1.72^\circ$, L = $17.67 \pm 1.67^\circ$] and scapholunate angle (SLA) [R = $43.70 \pm 3.60^\circ$, L = $45.10 \pm 3.44^\circ$]. The radial tilt was observed to be identical in the left and right wrists, while the capitulate and scapholunate angle were observed to be asymmetrical, with the left significantly greater than the right ($P < 0.01$). All right and left wrist parameters were significant inter-predictors ($r > 0.75$; $P < 0.01$), while only the R & L-RT correlated with R-CLA ($r > 0.302$; $P < 0.033$) and L-CLA ($r > 0.347$; $P < 0.013$). **Conclusion:** It could be concluded that there was no sex difference in angular wrist parameters and asymmetry was observed. The variation in the arrangement of wrist bones in both hands could be associated with mechanical impact as a result of use and this must be taken into consideration when evaluating unilateral wrist diseases.

Keywords: Wrist x-rays, angular parameters, Nigerians.

INTRODUCTION

Among the various imaging techniques for investigating the human systems, plain radiography (X-ray) has proven to be the most relied upon in the assessment of the bony anatomy of the wrist.^[1,2] However, the morphometric interpretation of the wrist bone anatomy is dependent on the quality of the appearance and location of the bony landmarks which is significantly influenced by the positioning of the arm, forearm and wrist in relation to the x-ray beam.^[3-6]

The significant morphological variations observed at the wrist joint are certainly factors that could result in wrist abnormalities.^[4,5] Gilula and Chesaru measured the scapholunate angle and reported that $30-60^\circ$ was normal,^[7] while $60-80^\circ$ was questionably abnormal, and $>80^\circ$ out-rightly abnormal and the capitulate

angle of $<30^\circ$ was normal. The normal radial tilt was reported to have an average angle of 11° with a range of $2-20^\circ$.^[8] In the evaluation of carpal instability, the scapholunate and capitulate angles are often investigated,^[7] while radial tilt provides valuable insight into wrist fractures.^[8] Studies have shown that age, sex, race, side and hand dominance and work-related variation in wrist joint parameters exist.^[1,9,10]

In defining the relationship between the left and right side of the hand, Zdravkovic and Sennwald postulated that in unilateral wrist disease,^[11] the opposite unaffected healthy hand can be used as a standard; hence reference to a normal value might not be necessary. However in a more recent study by Jafari et al.,^[11] they reported that variations exists between the measurements of the right and left wrists for ulnar variance, radial tilt of distal radius and radial inclination. Therefore, this study was carried out to establish normal values for angular wrist parameters

from lateral wrist X-rays; and in the process, investigate the existence of sex and side differences and highlight its role in clinical anatomy.

Name & Address of Corresponding Author

Aigbogun (Jr) E.O,
 Department of Human Anatomy, Faculty of Basic Medical
 Sciences, College of Health Sciences, University of Port
 Harcourt, Rivers State, Nigeria
 E-mail: eric_aigbogun@uniport.edu.ng

MATERIALS AND METHODS

Study design

This was a single-hospital based prospective cross-sectional descriptive study; involving a total of 100 standard lateral wrist x-rays (with neutral rotation) obtained from 50 adult Nigerians within ages 20-60 years. The study inclusion criteria was that the wrist radiographs must show skeletal maturity with no post-traumatic or surgical remodelling. The exclusion criteria include; previous history of hand or wrist trauma or fracture, rheumatologic, musculoskeletal disease and congenital anomaly.^[12] Radiographs which did not meet the standard criteria recommended by Palmer.^[13] Before measurements were taken, the radiographs were reviewed by attending consultant radiologist and an orthopaedic hand surgeon.

Data collection: landmarks and measurements

Radial tilt, capitolunate and scapholunate angles were measured on the lateral view. The capitolunate angle was defined as the angle formed by a line drawn along the axis of the mid-portions of the convex shaped proximal third metacarpal [Line C] and that of the proximal surface of the capitate [Line B] [Figure 1].^[14] The scapholunate angles was defined according to Jafari et al.^[1] It was defined as a line A which was taken from a point on the anterior pole to the posterior pole of the lunate bone and line B was drawn as a line perpendicular to line A. Line C, was a line drawn from the anterior surface of the scaphoid bone and parallel to the axis of the scaphoid bone. The scapholunate angle was seen as the angle between lines B and C [Figure 2]. Line A is a line drawn along the longitudinal axis of the distal end of the radius. Line B is a horizontal line perpendicular to line A. Line C is a line drawn to align with the articular surface of the distal radius. The radial tilt is the angle formed

between lines B and C.^[1]

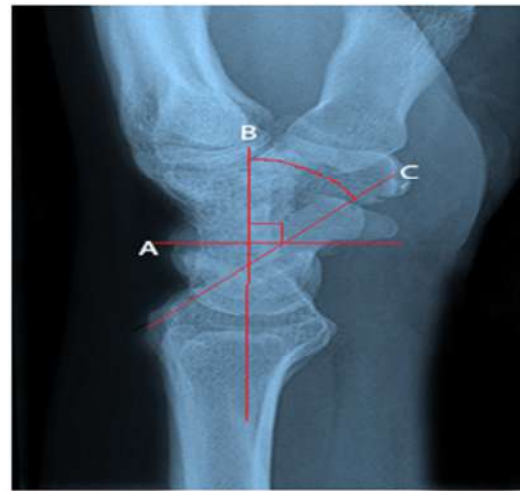

Figure 1: Capitolunate angle

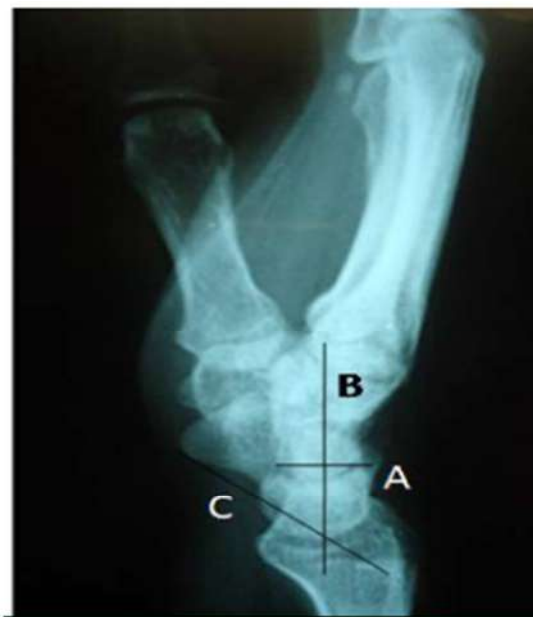

Figure 2: Scapholunate angle

Data Analysis

All the statistical analysis were carried out using XLSTAT (Addinsoft Version 2015.4.01.21575). Data were analysed as a single population and in the groups (male and female as sex group, and right side and left as side group). ANOVA and Paired Sample t-test were used for comparing the means of the sex and side groups respectively. The level of significance was set at $P < 0.05$.

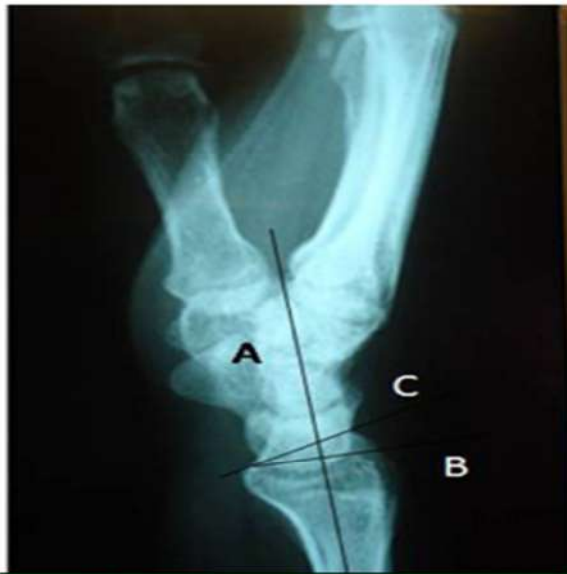

Figure 3: Radial tilt

Ethical considerations

Ethical clearance with reference number UPH/R&D/REC/04 was obtained from the University of Port Harcourt Ethical Review Committee of the School of Graduate Studies. Subjects used in this study were volunteers who were able to give spoken and written consent.

RESULTS

The results of the measured angular wrist dimensions were presented in [Table 1-3] and [Figure 1-5]. The descriptive characteristics of the measured wrist parameters and tests of sex difference in mean using ANOVA was presented in [Table 1]. The side comparison was presented in [Table 2] while the correlation between the measured parameters was reported in [Table 3]. The scatter plots (with regression equations) for significant correlates were presented in Figure 4a-e.

Mean values and sex difference

The mean age for male was 36.77±13.54years (range; 20-55years) while female was 36.76±13.35years (range; 20-55years). The R & L radial tilt (RT); male 14.38±2.86° (range 10-20°) and female 13.71±1.94° (range 10-18°). R capitolunate angle (CLA); male 17.77±1.82° (range 14-21°) and female 17.17±1.58° (range 14-20°). L capitolunate angle (CLA); male 17.98±1.86° (range 14-22°) and female 17.33±1.40° (range 15-20°). R scapholunate angle (SLA); male 43.54±3.55° (range 35-55°) and female 43.88±3.72°

(range 36-52°). L scapholunate angle (SLA); male 44.69±3.40° (range 37-52°) and female 45.54±3.49° (range 38-55°) (Table 1). All measured wrist parameters were observed not to have any sex associated difference; R & L RT [F=0.941, P=0.337], R CLA [F=1.554, P=0.219], L CLA [F=1.908, P=0.174], R SLA [F=0.107, P=0.745], L SLA [F= 0.759, P=0.388] [Table 1].

Side difference

The test of asymmetry of the measured parameters in Table 3 showed that except the R&L RT which exhibited identicalness, the L & R- CLA (MD=-0.19, t=-3.060, P=0.004) and SLA (MD=-1.40, t=-5.109, P<0.001) were significantly asymmetrical; with the left having higher mean values [Table 2].

Intra-/Inter-predictability of parameters

The L & R side of all measured parameters were significant with r-values of >0.75. The right and left radial tilt showed significant positive correlation with R CLA (r=0.302, P=0.033) and L CLA (r=0.347, P=0.013) but negative and no-significant correlation with the R & L SLA (P>0.05). The correlation between the R & L CLA and R & L SLA were also negative and not significant (P>0.05). The significant corrections were presented in scatter plots in [Figure 4a-e].

Table 1: Mean, range (min-max) values of the measured wrist parameters and tests of sex associated mean difference using ANOVA

Parameter	Male [N=26]			Female [N=24]			F-test		Total [N=50]		
	Mean±S.D	Min	Max	Mean±S.D	Min	Max	F	P	Mean±S.D	Min	Max
R & L-RT (°)	14.38±2.86	10	20	13.71±1.94	10	18	0.941	0.337	14.06±2.46	10	20
R-CLA (°)	17.77±1.82	14	21	17.17±1.58	14	20	1.554	0.219	17.48±1.72	14	21
L-CLA (°)	17.98±1.86	14	22	17.33±1.40	15	20	1.908	0.174	17.67±1.67	14	22
R-SLA (°)	43.54±3.55	35	55	43.88±3.72	35	52	0.107	0.745	43.7±3.60	35	55
L-SLA (°)	44.69±3.40	37	52	45.54±3.49	38	55	0.759	0.388	45.1±3.44	37	55

Note: R=Right, L=Left, RT=Radial tilt, CLA=Capitolunate angle, SLA=Scapholunate angle, S.D=Standard deviation, F-value=Fisher's value, P-value=Probability value.

Table 2: Evaluation of laterality using paired sample t-test

Parameter	Comparison	Paired Differences			t-value	P-value	Inf.
		Mean	S.D	S.E			
RT (°)	The R & L values exhibited identicalness in dimension						
CLA (°)	R vs L	-0.2	0.44	0.062	-3.06	0.004	S
SLA (°)	R vs L	-1.4	1.94	0.274	-5.11	<0.001	S

Note: R=Right, L=Left, RT=Radial tilt, CLA=Capitolunate angle, SLA=Scapholunate angle, S.D=Standard deviation, S.E=Standard error, t-value=t-test calculated value, P-value=Probability value, Inf.=Inference (S=Significance, NS=Not Significance)

Table 3: Interpredictability of the angular wrist parameters.

Variables	R & L RT - (r)	R CLA - (r)	L CLA - (r)	R SLA - (r)
R CLA - (r)	0.302			
P-value	0.033			
L CLA - (r)	0.347	0.967		
P-value	0.013	<0.001		
R SLA - (r)	-0.095	-0.118	-0.144	
P-value	NS	NS	NS	
L SLA - (r)	-0.124	-0.171	-0.211	0.849
P-value	NS	NS	NS	<0.001

Note: R=Right, L=Left, RT=Radial tilt, CLA=Capitolunate angle, SLA=Scapholunate angle, r=Pearson's correlation, P-value=Probability value, NS=Not Significance.

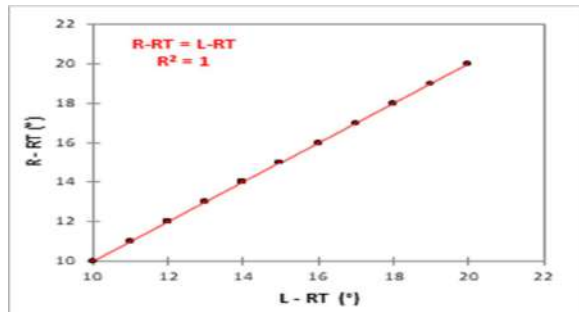


Figure 4a: Scatter plot of right radial tilt (R-RT) against left radial tilt (L-RT)

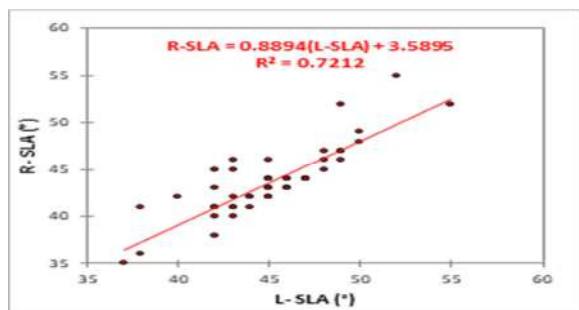


Figure 4b: Scatter plot of right scapholunate angle (R-SLA) against left scapholunate angle (L-SLA).

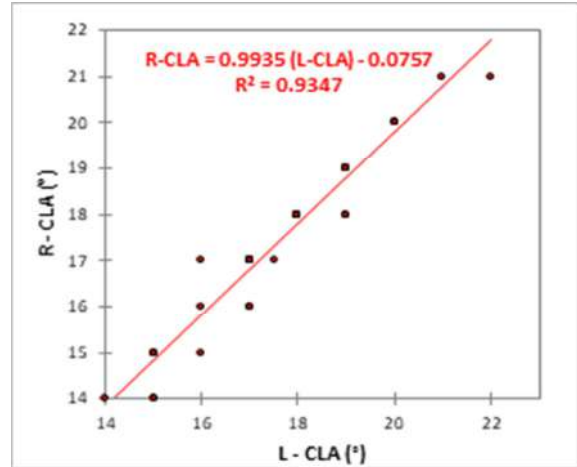


Figure 4c: Scatter plot of right capitulate angle (R-CLA) against left capitulate angle (L-CLA)

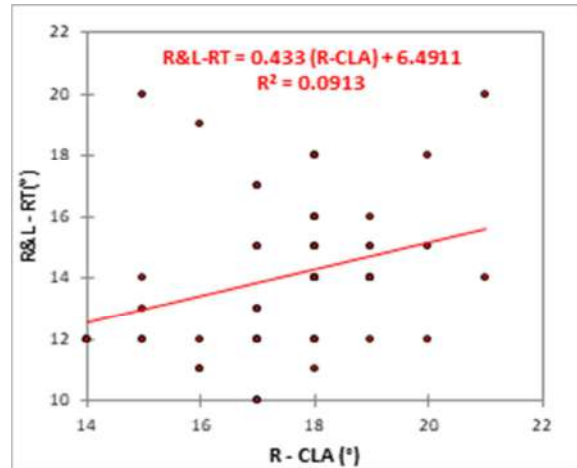


Figure 4d: Scatter plot of right and left radial tilt (R&L-RT) against right capitulate angle (R-CLA).

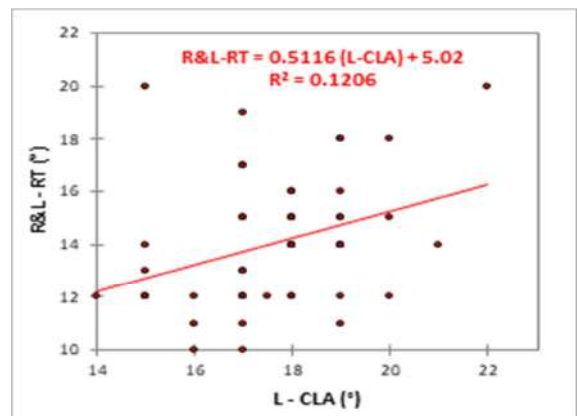


Figure 4e: Scatter plot of right and left radial tilt (R&L-RT) against left capitulate angle (L-CLA)

DISCUSSION

It is an unarguable fact that there exist a significant relationship between wrist morphometry and susceptibility to wrist dislocation, fracture and diseases (Gelber et al., 1975; Youm et al., 1980; Tsuge et al., 1993; Watanabek et al., 1993; Lamas et al., 2000 and Osamu et al., 2002; Larsen et al., 1991; Schuind et al., 1996; Jafari et al., 2012);^[1,9,10,15-20] however differences in sex, race, hand dominance, use and type of occupation have increased the morphometric variations in these values across regions,^[1,4,5,9,10] thus creating a slimmer window for clearly differentiating physiologic variant from pathological abnormalities. Nevertheless, these difficulty will be reduced when country specific normative data are made available.^[14,21]

Capitolunate angle and scapholunate angle

In this study, the CLA and SLA had a range of 14° to 22° and 35° to 55° respectively, which fell within the normal range reported by Gilula and Chesaru and Tischler et al.^[7,22] Values above the reported range suggests a scapholunate advanced collapse is characterised by abnormal increase in the scapholunate interval and forward movement of the capitate bone and characteristic tilting towards the dorsum of the scaphoid bone (Chang et al., 2014).^[23]

Radial tilt

This studied population had a radial tilt range of 10-21° which was within the normal range of 11° (range; 2-20°) reported by Smithuis.^[8] Even when compared to the mean values of 10-25° reported by Greenspan and Wood and Berquist,^[24,25] the values in this study were all within their documented normal range. A negative palmar tilt indicates dorsal angulation of the distal, radial articular surface which suggest the existence of a distal radial fracture.^[26]

Laterality

In this study, the Left and right SLA and CLA were observed to be significantly asymmetrical with an identical left and right RT. Zdravkovic and Sennwald suggested alternate use of values of the opposite hand in cases of unilateral wrist diseases without reference to a normal values.^[11] However, the observed asymmetry reaffirms a recent study by Jafari et al.;^[11] as they observed significant variations between measurements of the right and left wrists for radial inclination, radial tilt and ulnar variance and hence the unaffected healthy side does not provide a better reference than the normal values gotten from data bases for the above wrist parameters. The findings on radial tilt conformed to that of Zdravkovic and Sennwald but not Jafari et al.^[11,11] Sex, age and hand dominance have been reported to

influence wrist morphometry thus creating differences in side.^[9,10]

Intra-/inter-predictability

In this study, The radial tilt angle for the left and right were identical which conformed to the findings of Zdravkovic and Sennwald.^[11] Also, the right capitulate angle and scapholunate angles correlated significantly with their left side, though the two wrist parameters were bilaterally asymmetrical.

CONCLUSION

This research have established normative data for the radial tilt, capitulate and scapholunate angles for the Nigerian population, which could serve as a comparative reference values for diagnosis of wrist diseases and abnormalities. All measured values were within establish normal values and the parameters did not exhibit sex difference. The variation in the arrangement of wrist bones in both hands could be associated with mechanical impact as a result of use. In cases of unilateral wrist disease, the alternative use of the opposite wrist parameters rather than making references to normative values is therefore not recommended.

Recommendation

This study was limited to three angular wrist parameters, therefore it is recommended that additional significant angular dimensions with a wider population and the inclusion of patients with wrist trauma, fracture and disease be studied, so as to assure comparative evaluation of deviations from the normal.

Acknowledgements

The authors are highly grateful to the M.D of Orange Diagnostic Centre Dr. Nnabuchi Maurice A for availing us the opportunity to utilize his facility and personnel for this study.

REFERENCES

1. Jafari, D., Taheri, H., Shariatzade, H., Mazhar, F.N., Jalili. A. Ghahramani, M. Radiographic indices in one hundred fifty normal Iranian wrists. *Med J Islam Repub Iran.* 2012; 26(3): 132-139.
2. Dornberger JE, Rademacher G, Mutze S, Eisenschenk A, Stengel D. Accuracy of simple plain radiographic signs and measures to diagnose acute scapholunate ligament injuries of the wrist. *Eur Radiol.* 2015; 25(12): 3488-3498.
3. Friberg, S., and Lundstrom, B. (1976). Radiographic measurements on the radio-carpal joint in distal radial fractures. *Acta Radiologica [Diagn] (Stockh).* 1976; 17(6): 869-876.

4. DiBenedetto, M.R., Lubbers, L.M., and Coleman, C.R. (1991). Relationship between radial inclination angle and ulnar deviation of the fingers. *J Hand Surg Am.* 1991, 16 (1): 36-39.
5. Frederic A, Ronald L. A normal data base of posteroanterior roentgenographic measurements of the wrist. *J Bone Joint Surg Am.* 1992; 74:1418-1429.
6. Koh KH, Lee HI, Lim KS, Seo JS, Park MJ. Effect of wrist position on the measurement of carpal indices on the lateral radiograph. *J Hand Surg (Eur Vol).* 2013; 38(5): 530–541.
7. Gilula LA, Chesaru I. Wrist - Carpal instability. Mallinckrodt Institute of Radiology Washington University St. Louis, Missouri, USA and the Westeinde hospital, The Hague, Netherlands. 2008; Available at <http://www.radiologyassistant.nl/en/p42a29ec06b9e8>.
8. Smithuis R. Wrist - Fractures. Radiology department of the Rijnland Hospital in Leiderdorp, the Netherlands. 2008; Available at <http://www.radiologyassistant.nl/en/p476a23436683b/wrist - fractures .html>.
9. Larsen CF, Mathiesen FK, Lindequist S. Measurements of carpal bone angles on lateral wrist radiographs. *J Hand Surg Am.* 1991; 16(5): 888-893.
10. Schuind F, Alemzadeh S, Stallenberg B, Burny F. Does the normal contralateral wrist provide the best reference for X-ray film measurements of the pathologic wrist? *J Hand Surg Am.* 1996; 21(1): 24-30.
11. Zdravkovic V, Sennwald GR. A new radiographic method of measuring carpal collapse. *Bone Joint Surg [Br].* 1997; 79-B: 167-169.
12. Jafari D, Najd M.F, Jalili A, Zare S, Hoseini T.S. The Inter and Intraobserver Reliability of Measurements of the Distal radius radiographic indices, *Shafa Ortho J.* 2014 ; 1(2): e33.
13. Green DP, Pederson WC, Hotchkiss RN, Wolfe SW. *Greens Operative Hand Surgery.* 2005; 645-710.
14. Gelber Man RH, Salamon PB, Jurist JM, Posch JL. Ulnar variance in kienbock's disease. *J Bone Joint Surg (Am).* 1975; 57: 674 - 676.
15. Guglielmi G, Vankuijk C, Genant HK. *Fundamentals of hand and wrist imaging.* Springer-Verlag. Berlin Heidelberg, New York . 2001; (5). 56.
16. Lamas C, Mir X, Liusa M. Dorsalateral Biplane closing radial osteotomy in zero variant cases of Kienbock's disease. *J Hand Surg Am.* 2000; 25: 700-709.
17. Osamu SF. Lateral closing wedge osteotomy of the distal radius for advanced stages of Keinbock's disease. *J Hand Surg Am.* 2002; 27: 31-36.
18. Tsuge S, Nakamura R. Anatomical risk factors for keinbock's disease. *J Hand Surg Brit.* 1993; 18: 70-75
19. Watanabe T, Takahara M, Tsuchida H, Yamahara S, Kikuchi N, and Ogino T. Long-term follow-up of radial shortening osteotomy for Kienbock disease. *J Bone Joint Surg (Am).* 2008; 90: 170-511.
20. Youm Y, Flatt AE. Kinematics of the wrist. *Clin Orthop Relat Res.* 1980; 149: 21-32.
21. Mishra PK, Nagar M, Gaur SC, Gupta A. Morphometry of distal end radius in the Indian population: A radiological study. *Indian J Orthop.* 2016; 50(6): 610-615.
22. Tischler BT, Diaz LE, Murakami AM, et al. Scapholunate advanced collapse: a pictorial review. *Insights into Imaging.* 2014; 5(4):407-417.
23. Chang IYJ, Mutnal A, Evans P, Sundaram M. Kienbock's disease and scapholunate advanced collapse. *Orthop.* 2014; 37(9), 578: 637-639.
24. Greenspan A. *Orthopedic Radiology: A practical approach.* Philadelphia, Pa: JB Lippincott. 1988: 4.3-4.12.
25. Wood MB, Berquist TH. *Imaging of orthopedic Trauma.* New York, NY: Raven Press. 1992; 749-870.
26. Hanel DP, Jones MD, Trumble TE. Wrist fractures. *Ortho Clin North Am.* 2002; 33(1): 35-37.

Copyright: Academia Anatomica International is an Official Publication of "Society for Health Care & Research Development". This is an open-access article distributed under the terms of the Creative Commons Attribution Non-Commercial License, which permits unrestricted non-commercial use, distribution, and reproduction in any medium, provided the original work is properly cited.

How to cite this article: Omadachi SE, Gwunireama IU, Aigbogun EO. Radiologic Assessment of Angular Wrist Parameters Of Asymptomatic Nigerians. *Acad. Anat. Int.* 2017;3(2):52-57.

Source of Support: Nil. **Conflict of Interest:** None declared.