

Alizarin Red-S Protocol for Skeletal Staining during Fetal Period in Rabbit

Reda Mohamed^{1,2}

¹Department of Basic Veterinary Sciences, School of Veterinary Medicine, Faculty of Medical Science, the University of the West Indies, Trinidad and Tobago, West Indies.

²Department of Anatomy and Embryology, Faculty of Veterinary Medicine, Beni-Suef University, Beni Suef 62511, Egypt.

Date of Submission: 18-01-2018

Date of Acceptance: 16-03-2018

Date of Publishing: 21-05-2018

ABSTRACT

Background: The main purpose of this study was to give detailed information on the staining protocol of Alizarin Red-S to detect the normal and abnormal skeleton of rabbit fetus. **Methods:** Eleven (9 females and 2 males) of adult rabbit weighing 3-3.5 kg were used. The female rabbits were left with buck to become pregnant then were classified into a treatment and a control group. The former group received oral doses of 400mg/kg of sodium valproate for 15 days starting from the 6th day after mating until 20th day of pregnancy, while the second received water in the same period. The pregnant rabbit was slaughtered at the 29th day of pregnancy. The live rabbit fetuses were collected. The staining protocol included fixation, dehydration, clearing, staining and preservation. The fetuses were examined under dissecting microscope and photos were taken for documentation. **Results:** The staining protocol made the rabbit fetuses to be clear enough to see their skeleton through the surrounding tissue. The axial skeleton including skull with mandible, vertebral column, ribs and sternum and the appendicular skeleton including the bones of the fore-and hindlimbs took the stain and became red in color. The macroscopic skeletal disorders of the fetuses of the treatment group were observed. The ossification centres were assessed. **Conclusion:** This protocol which depended on fixation by 95% ethanol, clearing by 1% potassium hydroxide and staining by 0.001 % Alizarin Red-S was effective in detecting normal and abnormal fetal skeletal morphology.

Keywords: Alizarin red, Skeleton, Rabbit, Fetuses

INTRODUCTION

The rabbit is considered as a good source of meat and fur production and it is valued as a popular live laboratory animal used in laboratory research as it has the ability to adapt itself to changes in the environment and it gives offsprings monthly. Bones are derived from the paraxial mesoderm during fetal period. Osteogenesis is the transformation of a pre-existing mesenchymal tissue into bone tissue and this includes intramembranous and endochondral ossification. The

former ossification is the mesenchymal tissue differentiates into bone directly. While, endochondral ossification is the mesenchymal tissue differentiates into cartilage which is then replaced by bone cells. The staining of the skeleton of the fetus in laboratory animals is an important step to investigate the normal skeleton and skeletal teratology macroscopically.

Alizarin Red-S has been used for many years in bone staining and the first staining of the fetus skeleton was done by Alden.^[1] This stain acts as a color indicator for bony parts of the body due its high affinity for calcium ion binding.^[2,3] There are many advantages in the use of Alizarin Red-S to stain the bones such as avoiding the loose of small bones, the bones and joints stay fix in position and different animals can be stained in the same time without mixing of their bones.

Administration of antiepileptic drugs such as calcium valproate during pregnancy causing skeletal abnormalities in rabbit.^[4] The study was conducted to

Name & Address of Corresponding Author

Reda Mohamed
Department of Basic Veterinary
Sciences, School of Veterinary
Medicine, Faculty of Medical Sciences,
The University of the West Indies,
St. Augustine, Republic of Trinidad and
Tobago, West Indies.
Email: reda.mohamed@sta.uwi.edu

use the Alizarin Red stain as an indicator for normal skeletons and abnormal skeletons in rabbit fetuses after administrating sodium valproate in pregnant rabbits during organogenesis as well to assess the ossification centers.

MATERIALS AND METHODS

Animal preparation and drug administration: About eleven adult sexually mature (3-3.5 kg), virgin apparently healthy wild rabbits of both sex (9 females and 2 males) were used for this study. The rabbits were collected from local farm in Trinidad and Tobago and the procedure was ethically approved by the Campus Ethics Committee of the University of the West Indies, Trinidad and Tobago (Ref: CEC 149/03/17). The rabbits were housed in separate cages under standard condition with standard diet and free water supply for two weeks to make sure that they were free from diseases and pregnancy. Rabbits were classified into two groups; treatment (6 rabbits) and control groups (3 rabbits). Each female rabbit in both groups was left with fertile buck in his cage in the late afternoon and this day was considered as day zero pregnancy.^[5] Since the ovulation occurred about 10-12 hours after mating,^[6] so about 12 hours were discarded from the calculation to arrive at the true age.^[7,8] The drug was administrated for rabbits for the treatment group as oral doses of 400mg/kg of Sodium valproate for 15 days starting from the 6th day after mating until the 20th day of pregnancy, while the control group received water for the same period. The pregnancy was verified by ultrasound and abdominal palpation. The pregnant rabbit was sacrificed at the 29th day of pregnancy. The peritoneal cavity of the rabbit was opened and the intact uterus was removed. A longitudinal incision was made in the uterus and the live fetuses were collected.

Skeletal staining technique: Some safety precautions were taken such as wearing gloves, lab coat and goggles to avoid chemicals hazard. About 40 live rabbit fetuses from the control and treatment groups were used for this study. The fetuses were scarified [Figure 1] and the abdominal and thoracic contents were evacuated. They were placed in 95% ethanol for fixation by dehydration from 4-7 days. After dehydration, the fetuses were rinsed in distilled water to remove the residue of the ethanol. The fetuses were put in pure acetone for 1-3 days to remove the fat. The skin, epidermis of the hands and feet, salivary glands, esophagus, trachea, eyes, the pad of fat between the vertebrae and scapula and the muscles of the dorsal aspect of the neck were removed by the forceps. Then the rabbit fetuses were put in 1% potassium hydroxide solution (10gm potassium hydroxide in 1000 ml

distilled water) from 1-3 days until the skeleton became clear visible. Then the fetuses were put in a freshly prepared purple color of 0.001% Alizarin Red-S. (1mg Alizarin Red-S. in 100 ml of 1% potassium hydroxide) for skeleton staining from overnight to one day until the skeleton became red in color. The skeleton was cleared by putting the fetuses in a mixture of 1% potassium hydroxide and 20% glycerol for two days. Some skeletons remained unclear, so we repeated the step of clearance (1% potassium hydroxide solution). Finally, the skeletons were stored in a 1:1 mixture of 95% ethanol and glycerol. The stained skeleton of the rabbit fetuses were examined under Stereo-microscope to examine the axial and appendicular skeletons. The gross photos were taken for documentation.

Assessment of ossification of the fetuses via the Alizarin Red-S: The ossification of the axial and appendicular skeletons of the rabbit fetuses was estimated according that according the degree of stain coloration of Alizarin Red-S,^[9,10] so the ossified parts had red colour while the incomplete ossified parts had less red colour. On the other hand no colour was seen in un-ossified parts.

RESULTS

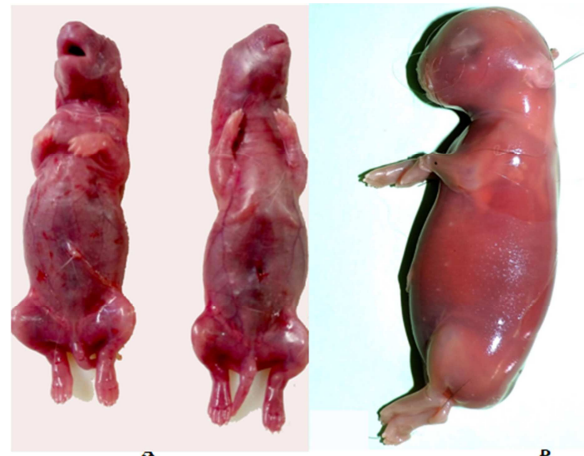

Figure 1: Photograph showing samples of the 29th day old fetuses of the control group (A) and treatment group (B)

The axial and appendicular skeletons of the rabbit fetuses of the treatment and control groups were stained red, while the muscles did not take the stain. So that it was easily to identify the details of the parts of the normal skeletons and these with anatomical disorders. The fetuses were clear and the skeletons were seen through them. In the fetuses of the control group, the axial skeleton including skull with mandible, vertebral column, sternum, ribs and caudal

vertebrae were normal with complete ossification. The appendicular skeleton consisted of forelimbs and hind limbs. The bones of the forelimb including scapula, humerus, radius and ulna, metacarpals and phalanges were normal with complete ossification. The bones of the hindlimb including os-coxae, femur, tibia, metatarsals and phalanges were normal with complete ossification [Figure 2]. Some of the fetuses of the treatment group showed anomalies in the ribs such wavy ribs with opposite direction [Figure 3].

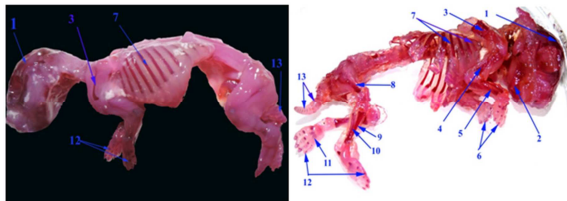


Figure 2: Photograph of 29th day old fetuses of the control group (A&B) stained by Alizarin Red-S showing the ossified bony parts of skeleton. 1. Skull bones; 2. Mandible; 3. Scapula; 4. Humerus; 5. Radius; 6. Phalanges of the forelimb; 7. Ribs; 8. Femur; 9. Tibia; 10. Fibula; 11. Metatarsals; 12. Phalanges of the hind limb; 13. Caudal vertebrae.

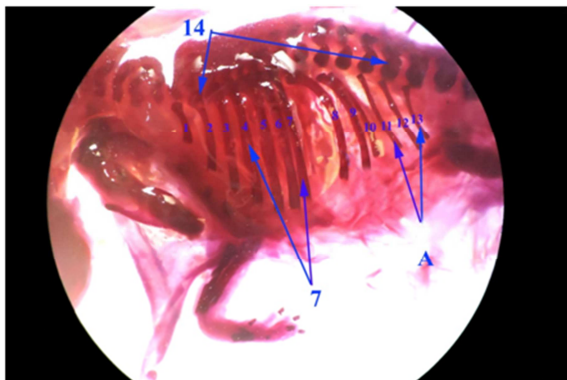


Figure 3: Photograph of 29th day old fetuses of the treatment group stained by Alizarin Red-S under the dissecting microscope showing anomalies of some ribs. 7. Normal Ribs; 14. Thoracic vertebrae; A. Abnormal ribs (11-13).

DISCUSSION

The current investigation indicated that the use of Alizarin Red-S was the best method to detect the osteogenesis in laboratory animals such rabbit fetus simulated that reported in mouse.^[11] Moreover the present result as well as that in mouse stated that the red color of the bones was due to the high affinity of the Alizarin Red-S to the calcium ions in the bones.^[12] The obtained results were parallel to those described in mouse that it was better to fix the rabbit fetuses by 95% ethanol than in formalin because the staining by

Alizarin Red-S depends upon the amount of the calcium in the bone,^[11] so that formalin can cause decalcification and decrease the affinity of the stain as well. Fixation of the mouse is done by either 95% alcohol or 10% formalin is not necessary because the fixation prolongs the time of potassium hydroxide treatment and decreases the quality of the specimens. However, some samples such as salamanders may disintegrate if it is put in in potassium hydroxide without fixation.^[13] However, 95% ethanol, 3% potassium hydroxide and Alizarin Red-S are used for fixation and clearing. The ethanol is used as a fixative in young samples, while buffer formaldehyde and ethanol were used as a fixative in adult samples.^[14]

The current work under discussion revealed that the prolonged period of fixation gave successful clearing and staining processes, however the short fixation prolonged the cleaning process which was undesirable. Moreover, it was desirable to put the fetuses in pure acetone after fixation to remove fat; similar results were recorded in mouse.^[11,12]

The current work under discussion revealed the process of clearing using 1% potassium hydroxide was the best method for clearing process however, precaution should be taken because the high concentration of this chemical can cause the fetuses to be friable, fall apart of the bones and affect the stain as well; similar results were recorded in mouse.^[11,12] On the other hand, the quicker and better cleaning process is done in mouse by using 2% potassium hydroxide.^[12] The ultra-violet light is used in the clearing process.^[15] The initial clearing by glycerol and 70% ethyl alcohol is followed by benzyl alcohol as an additional clearing, well-cleared specimens rat fetuses in a short time is gotten however benzyl alcohol is not recommended due to its unpleasant fumes. Moreover the latter authors added that the 2% concentration of potassium hydroxide can be successfully used for staining rabbit fetuses.^[16]

The obtained results were parallel to those described in mouse that the putting many animals in one container should be avoided to prevent spoilage.^[12]

The Alizarin Red-S solution should be made freshly in small quantities and with suitable concentration (medium pink color) because the concentration of the stain cannot stay for prolonged period and the excessive stain can color the soft tissue around the bones and bones and that detracted the bone appearance which was not desirable, a result which was in a line with that mentioned in mouse.^[13]

The current work under discussion revealed that excessive staining of Alizarin Red-S was removed by repeat the clearance step by putting the fetuses in 1% potassium hydroxide solution for few days; similar result was recorded in mouse.^[13]

The timing of the staining protocol of Alizarin Red-S differed according to the size of the animal, temperature

and concentration of the solution; similar result was recorded in mouse.^[13]

There were some safety precautions were taken during the protocol such as wearing gloves, lab coat and goggles to avoid chemicals hazards such as potassium hydroxide which is irritant to eyes and skin, corrosive and can cause burn and acetone which is toxic in digestion and irritation to respiratory system on inhalation as well as it is flammable.

CONCLUSION

The Alizarin Red-S was an effective protocol in assessing rabbit fetal skeletal morphology. This protocol depended on fixation by 95% ethanol, clearing by 1% potassium hydroxide and staining by 0.001 % Alizarin Red-S.

Acknowledgements

The author is grateful to Charlene, Kavita, Joshila, Dominic, Lister and Samuel for their assistance.

REFERENCES

1. Alden BD. A note on the staining of the skeleton of cleared specimens with Alizarin red S. *Stain Technology*. 1962; 1: 123-124.
2. Mall FP. On ossification centers in human embryos less than 100 days old. *Amer. Jour. Anat.* 1906; 5:433-458.
3. Staples R and Schnell VL. Refinements in rapid clearing technic in the potassium hydroxide alizarin red S method for fetal bone. *Stain Technol.* 1964; 39: 61-3.
4. Petre JA, Anderson JA, Sakowski R, Fitzgerald JE and de la Iglesia FA. Teratogenesis of calcium valproate in rabbits. *Teratology*. 1986; 34(3):263-9.
5. Diaz-Hernandez VA, Leon del Rio, Zamora M and H. Merchant-Larios H. Expression profiles of SRY and SOX9 in rabbit gonads: The classical model of mammalian sex differentiation. *Sexual Development*. 2008; 2 (3): 152-166.
6. Hayashi T, Kageyama Y, Ischizaka K, Kihara K and Oshima H (2002). Involvement of apoptosis in the control of Sertoli cells and pre-meiotic germ cell numbers in the developing rabbit testis. *Andrologia*. 2002; 34 (1): 34-40.
7. Mohamed R, Adam Z, Gad M and Mazher K. The morphogenesis of the sexually indifferent gonads in the rabbit. *International Journal of Clinical and Developmental Anatomy* 2017; 3 (6): 57-63.
8. Mohamed R, Adam Z, Gad M and Mazher K. Microscopic anatomy of Sertoli and Leydig cells during fetal development in baladi rabbit. *International Journal of Animal Science and Technology* 2018; 2 (1): 1-5
9. Burdan F, Szumilo J, Dudka J, Klepacz R, Błaszczyk M, Solecki M, Korobowicz A, Chafas A, Klepacki J, Palczak M, Zuchnik-Wrona A, Hadała-Kiś A, Urbanowicz Z and Wojtowicz Z. Morphological studies in modern teratological investigations. *Folia Morphol (Warsz)*. 2005; 64 (1):1-8.
10. Abdel Salam G and Allam AA .The effects of valproic acid on the skeletal development and the ameliorative effects of combined use of folic acid and vitamin E in pregnant albino rats. *International Journal of Clinical and Developmental Anatomy*. 2015; 1(3): 70-78.
11. Sadeghi F. Two separated protocols with the most important comments for skeletal staining in embryonic and adulthood period in laboratory animals. *Anatomical Sciences*. 201; 11(2): 87-92.
12. Erdogan D, Kadioglu D and Peker T. Visualization of the fetal skeletal by double staining with alizarin red and Alcian blue. 1995; 6: 55-58.
13. Green and Margaret C. Rapid method for clearing and staining specimens for the demonstration of bone. *The Ohio Journal of Science*. 1952; 52: 31-33
14. Schultze OMS. Grundriss der Entwicklungsgeschichte des Menschen und der Säugethiere, für Studierende und Ärzte. London: Forgotten Books; 1897.
15. Salaramoli J, Sadeghi F, Gilanpour H, Azarnia M and Aliesfehni T. Modified double skeletal staining protocols with Alizarin red and Alcian blue in laboratory animals. *Annals of Military and Health Sciences Research* 2015; 13:76-81
16. Hollister G. Clearing and dyeing fish for bone study. *Zoologica*. 1934; 12:89-101.
17. Whitaker J and Kathleen M. Double staining technique for rat fetus skeletons in teratological studies. *Laboratory Animals*. 1979; 1: 309-310.

Copyright: Academia Anatomica International is an Official Publication of "Society for Health Care & Research Development". This is an open-access article distributed under the terms of the Creative Commons Attribution Non-Commercial License, which permits unrestricted non-commercial use, distribution, and reproduction in any medium, provided the original work is properly cited.

How to cite this article: Mohamed R. Alizarin Red-S Protocol for Skeletal Staining during Fetal Period in Rabbit. *Acad. Anat. Int.* 2018;4(1):41-44.

Source of Support: Nil, **Conflict of Interest:** None declared.